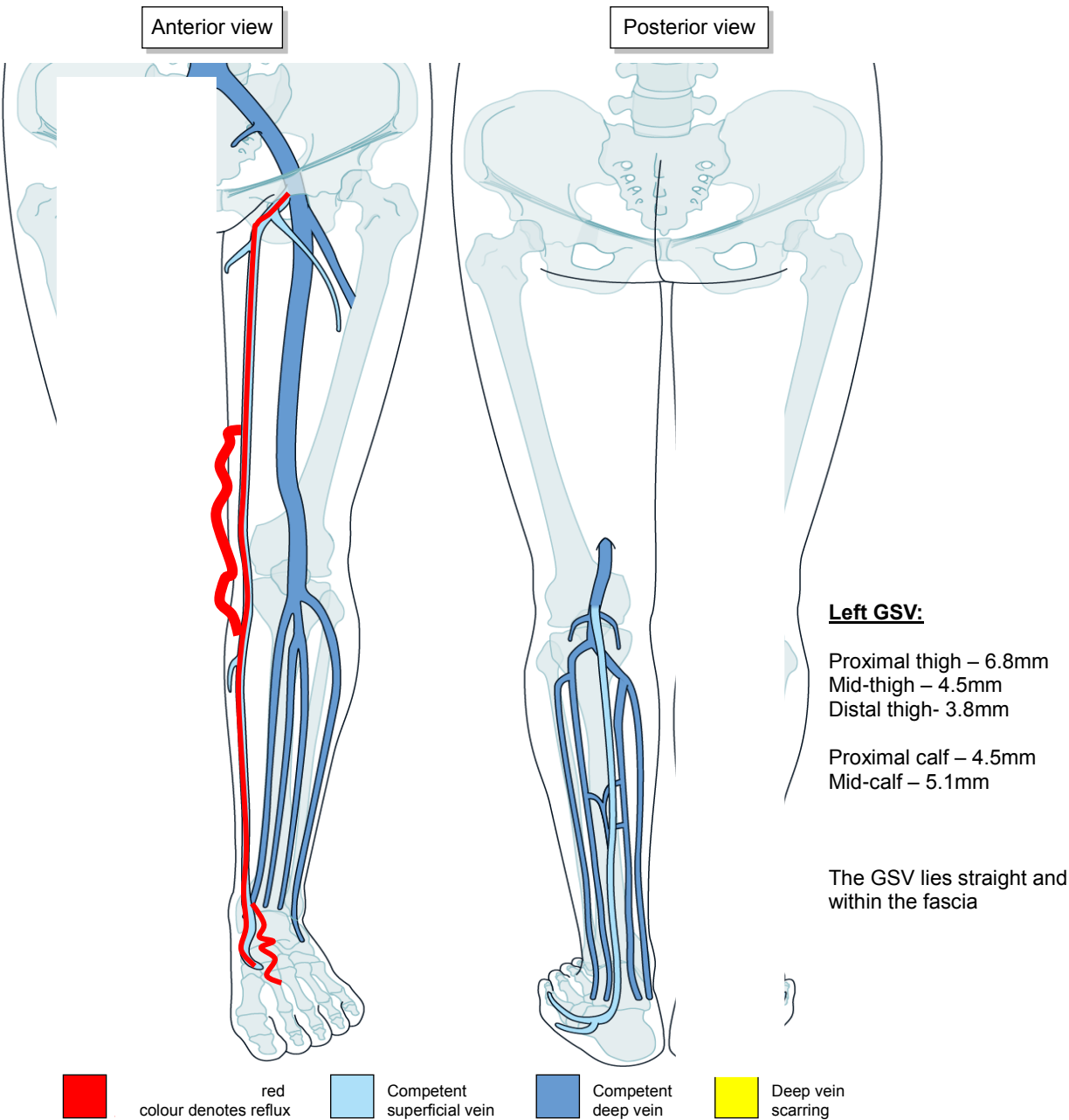


Vascular lab report

Assessed by: Suleman Choudhury



US Doppler lower limb veins Lt:

The Sapheno-Femoral Junction (SFJ) and Greater Saphenous vein (GSV) are patent and incompetent throughout. The GSV fills a large varicose vein (9mm) in the mid-thigh which refluxes back into the distal thigh GSV.

The Sapheno-Popliteal Junction (SPJ) and Short Saphenous vein (SSV) are patent and competent.

All deep veins are all patent and competent.

There appears to be an incompetent posterior tibial perforator below ankle level causing small varices (2.6mm) at the ankle.
